



Oncology Standards/Interoperability Summit

Panel 2 - Making systems more open

Imaging, Radiology Reporting, DICOM

David Clunie (dclunie@dclunie.com)

PixelMed Publishing

Background & Disclosures

- Owner, PixelMed Publishing, LLC
- Radiologist (once upon a time)
- Independent Consultant (various imaging vendors)
- Sub-contractor on NCI QIICR, BRIDG Imaging
- Editor of DICOM Standard

Published March 31, 2016 as 10.3174/ajnr.A4742

ORIGINAL RESEARCH
HEAD & NECK



Do Radiologists Report the TNM Staging in Radiology Reports for Head and Neck Cancers? A National Survey Study

B. Ko, U. Parvathaneni, P.A. Hudgins, and Y. Anzai

ABSTRACT

BACKGROUND AND PURPOSE: CT and MR imaging are widely used for the staging of head and neck cancer. Currently, there are no data regarding whether the primary tumor, nodes, metastasis (TNM) staging is routinely incorporated into radiology reports. We conducted a national survey to determine whether radiologists routinely address staging, in particular regarding T (primary tumor) and N (nodal).

MATERIALS AND METHODS: The survey was sent to 782 members of the American Society of Head and Neck Radiology. The survey asked whether they assign TN staging in reports. If they do assign TN staging, what are the reasons for doing so, and if not, what are the barriers or reasons for not including it in the radiology report? The method of measuring the size of the primary tumor and pathologic lymph nodes was also queried.

RESULTS: A total of 229 responses were returned (29.3% response rate). Approximately half (49%; 95% confidence interval, 43.55–54.5%) of the responders thought that incorporating TN staging is important. However, only 24.5% (95% confidence interval, 19.8%–29.2%) stated that they routinely assigned TN staging in their radiology reports. The most common barriers were being afraid of being inaccurate (59%) and being unable to remember the staging classifications (58.2%); 76.9% indicated that they measure a primary tumor in 3D.

CONCLUSIONS: Staging head and neck cancer based on imaging presents unique challenges. Nearly half of the responding radiologists think it is important to incorporate TN staging in radiology reports, though only a quarter of them routinely do so in practice.

ABBREVIATIONS: H&N = head and neck; TNM = (primary) tumor, nodes, metastasis



Do Radiologists Report the TNM Staging in Radiology Reports for Head and Neck Cancers? A National Survey Study

B. Ko, U. Parvathaneni, P.A. Hudgins, and Y. Anzai

though only a quarter of them routinely do so in practice.

ABSTRACT

BACKGROUND AND PURPOSE: CT and MR imaging are widely used for the staging of head and neck cancer. Currently, there are no data regarding whether the primary tumor, nodes, metastasis (TNM) staging is routinely incorporated into radiology reports. We conducted a national survey to determine whether radiologists routinely address staging, in particular regarding T (primary tumor) and N (nodal).

MATERIALS AND METHODS: The survey was sent to 782 members of the American Society of Head and Neck Radiology. The survey asked whether they assign TN staging in reports. If they do assign TN staging, what are the reasons for doing so, and if not, what are the barriers or reasons for not including it in the radiology report? The method of measuring the size of the primary tumor and pathologic lymph nodes was also queried.

RESULTS: A total of 229 responses were returned (29.3% response rate). Approximately half (49%; 95% confidence interval, 43.55–54.5%) of the responders thought that incorporating TN staging is important. However, only 24.5% (95% confidence interval, 19.8%–29.2%) stated that they routinely assigned TN staging in their radiology reports. The most common barriers were being afraid of being inaccurate (59%) and being unable to remember the staging classifications (38.2%); 76.9% indicated that they measure a primary tumor in 3D.

CONCLUSIONS: Staging head and neck cancer based on imaging presents unique challenges. Nearly half of the responding radiologists think it is important to incorporate TN staging in radiology reports, though only a quarter of them routinely do so in practice.

ABBREVIATIONS: H&N = head and neck; TNM = (primary) tumor, nodes, metastasis

Radiology Reports Suck


- From a utility (to oncologist) perspective
 - lack of measurements
 - lack of adherence to formal response/staging criteria (RECIST, TNM, etc.)
- From a (semantic) interoperability perspective
 - template (outline) not structured (or standardized)
 - measurements not structured
 - observations not structured and coded

Why Radiology Reports Suck

- Free text dictation as prose narrative
- Structured authoring tools complex/unavailable
- Lack of incentives to do better
- Lack of discipline (self or externally imposed)
- Lack of systems to consume structured/coded content

Why Radiology Reports Suck

- Free text dictation as prose narrative
- Structured authoring tools complex/unavailable
- Lack of incentives to do better
- Lack of discipline (self or externally imposed)
- Lack of systems to consume structured/coded content

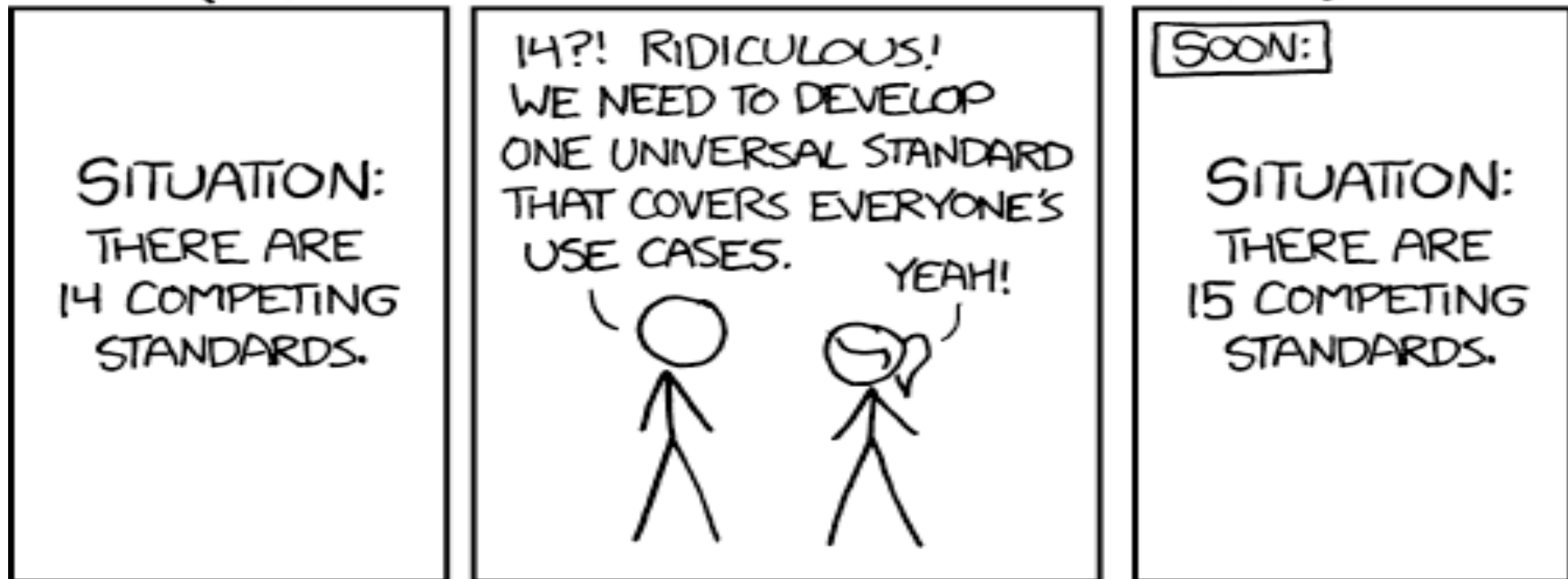

State of the Art: free text from voice dictation with no consistent structure and no codes beyond minimal for reimbursement, distributed by fax or in EHR as plain text

What about Encoding Standards?

- Have plenty of them and have had for years/decades:
- DICOM Structured Reporting – Diagnostic Imaging Report Templates
- HL7 Clinical Document Architecture – Diagnostic Imaging Report Templates (C-CDA, DICOM PS3.20)
- Have been helpful for machine measurements as input

HOW STANDARDS PROLIFERATE:
(SEE: A/C CHARGERS, CHARACTER ENCODINGS, INSTANT MESSAGING, ETC)



<https://xkcd.com/927/>

DICOM SR provides input to clinical reporting process

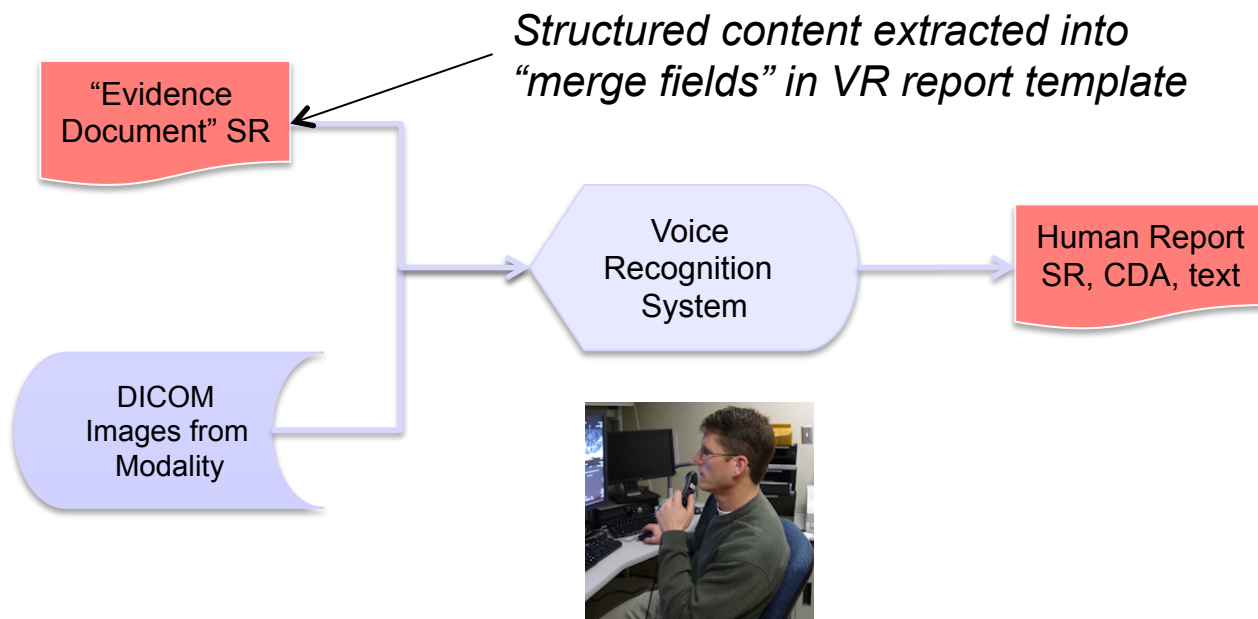


Image from David Weiss, Aunt Minnie 2013/01/18

What about Codes/Terminology?

- Have plenty of them too:
- SNOMED (used extensively in DICOM & DICOM SR)
- LOINC (measurements and procedures)
- FMA (anatomy)
- RadLex (supposed to fill the “SNOMED gap”)
- UMLS to unify them

What about Content Templates?

- Only more recently “standardized”:
- RSNA Reporting Initiative (outlines)
 - headings and sub-headings
 - some structure (pick lists)
- IHE Management of Radiology Report Templates (MRRT)
 - a standard for encoding such templates (constrained HTML5)



[Log in »](#)

- Informatics
- RSNA Image Share
- IHE
- MIRC
- Meaningful Use
- RadLex
- Reporting
- myRSNA®



Radiology Reporting Initiative

What is the Radiology Reporting Initiative?

The clinical report is an essential part of the service that we provide to our patients. The report communicates information to referring physicians, records information for future use, and serves as the legal record that documents the episode of care. Ideally, the radiology report should be consistent, comprehensive, easily managed, and "readable" to humans and machines alike.

The RSNA reporting initiative is improving radiology practice by creating a library of clear and consistent report templates. These templates make it possible to integrate evidence collected during the imaging procedure, including clinical data, coded terminology, technical parameters, measurements, annotations and key images. Twelve subcommittees of subspecialty experts and several leading radiology departments have created a library of more than 200 radiology report templates. The templates are free, and not subject to license restrictions on their reuse.

These report templates:

- Create uniformity and improve your communication with referring providers
- Enable your practice to meet accreditation criteria
- Help your practice earn pay-for-performance incentives

RSNA supports the MRRT ("Management of Radiology Report Templates") standard developed by the IHE Radiology Committee. RSNA encourages reporting vendors to adopt MRRT and to develop software products that enable radiologists to create high-quality radiology reports more efficiently.

CT Onco Lung Mass

[]

Clinical information

[]

Comparison

[None.]

Findings**Lung mass**

Size: [] cm

Volume: [] cm³

Location: [] (series [], image [])

Shape: [Spiculated | Round | Smoothly marginated]

Internal consistency: [Centrally calcified | Peripherally calcified | Ground glass | Fatty]

Local extent

Pleural surface: [No involvement.]

Chest wall: [No involvement.]

Airway: [No involvement.]

Vessels: [No involvement.]

Nerves: [No involvement.]

Regional extent

Lymph nodes: [No adenopathy.]

Distant metastases (chest and upper abdomen): [None.]

Other findings

Other findings [None.]

Impression

[]

Lung mass

Size: cm

Volume: cm³

Location: (series)

image)

Shape:

Spiculated

Internal consistency:

Centrally calcified

Local extent

Pleural surface: No involvement.

Chest wall: No involvement.

Airway: No involvement.

Vessels: No involvement.

Nerves: No involvement.

Regional extent

Lymph nodes: No adenopathy.

Distant metastases (chest and upper abdomen):
 None.

Other findings

None.

Anyone can use these templates—just like the original "Select" template library. On the "Open" template library, RSNA and ESR members can add and edit their own templates, and comment on and rate others' templates. [More information >>](#)

Add Template T-Rex Template Editor

Language Sort by

Template Title & Description	Specialty	Created	Last 30 Days	Rating & Language
ABD_PEL CT Routine ABD_PEL CT MEH report template	Computed Tomography, Emergency Radiology, Gastrointestinal Radiology, Genitourinary Radiology	May 14, 2015	68 views 0 comments	English
Akciğer grafisi Turkish Translation of the Chest Xray template		November 5, 2015	21 views 0 comments	★★★★☆ Turkish
Brain CT Generic Brain CT	Neuroradiology	June 30, 2014	38 views 0 comments	★★★★☆ English

Any Specialty	70
Breast Imaging	3
Cardiac Radiology	0
Chest Radiology	5
Computed Tomography	14
Diagnostic Radiology	14
Emergency Radiology	10
Gastrointestinal Radiology	13
Genitourinary Radiology	7
Head and Neck	6
Interventional Radiology	1

CT HCC screening | Open R... x +

https://open.radreport.org/template/0050112/ Search

open template library Search Login Contact Return to radreport.org 'Select' site

CT HCC screening

CT HCC screening

Spleen

Normal
Splénomegaly

Spleen Size cm

Ascites

None
Mild
Moderate
Severe

Focal Liver Lesions:
Lesions compatible with hepatocellular carcinoma by OPTN class 5 criteria:

Rate Template Download Template

Specialities

[Computed Tomography](#)
[Gastrointestinal Radiology](#)
[Oncologic Imaging](#)

Created

2015-03-01 11:08:00

Modified

2015-03-01 11:08:00

Views

529

Downloads

4

Rating

No ratings submitted

Language

English

Author

[Parag Tolat](#)

What about Incentives?

- Few/none
- No payment for “better” content or interoperability
 - not part of “pay for performance”
 - MU C-CDA plain text wrapper is not semantic interoperability
- No “accreditation” based on report quality criteria
 - BI-RADS, Lung-RADS for very specific applications
 - ASCO role – define what “customer” wants?
- Competitive pressure
 - send patients elsewhere for imaging

